

The cytoskeletal intermediate filaments alterations of rat colon after exposure to immobilization stress and the curative role of diazepam

Nabila I. El-Desouki¹; Gabry, M. S.² and Nagi. H. M²

¹ Department of Zoology, Faculty of Science, Tanta University, Tanta 31527, Egypt.

² Department of Zoology, Faculty of Science, Helwan University, Egypt

CORRESPONDENCE: Nabila Ibrahim El-Desouki, Department of Zoology, Faculty of Science, Tanta University, Egypt. **E-mail:** nabiladesoky@yahoo.com

ABSTRACT: The present work was planned to study the cytoskeletal intermediate filaments changes that may occur in the colon of the immobilized-stressed albino rats and the ameliorative role of diazepam injected intraperitoneally with therapeutic dose (0.1 mg/ kg b.w.). Sixty adult male albino rats weighing $110 \pm 5g$ were used and divided equally into 6 groups (10 animals / each), group(I) served as control rats; group(II) rats treated with diazepam; group (III) and (IV) served as stressed rats: in which the rats were immobilized individually for 2 hrs. daily for two durations (5 and 30 days, respectively); groups (V) and (VI) served as immobilized- stressed rats for 2 hrs daily for 5 and 30 days and treated with diazepam for 30 days, respectively. The results recorded a significant increase in sera cortisol of the stressed-rats for 5 and 30 days. Immunohistochemical results of colon demonstrated marked intense cytokeratin immunoreactivity at the apical part and the lateral borders of epithelial and goblet cells. Also, an obvious intense vimentin immunoreaction in the lamina propria and the blood vessels walls of the colonic mucosa of the immobilized-stressed rats for 2hrs/ daily for 5 and 30 days, these alterations were time-dependend. Treatment with diazepam resulted in decreased cortisol levels, marked improvement and restoration of the cytoskeletal proteins alteration. The results indicated that diazepam is recommended to be used as a curative drug to improve the disturbances in the cytoskeletal intermediate filaments of colon induced by stress.

KEY WORDS: Colon, Cytoskeleton, Immobilization stress, Diazepam, Rat.

INTRODUCTION

Stress can be defined as the sum of all the reactions of the body, which disturb the normal physiological condition and results in a state of the retained homeostasis (**Lttiyavirah & Sajid, 2014**). Stress activated the hypothalamic-pituitary-adrenal (HPA) axis that leads to a great release of adrenocorticotrophic hormone (ACTH) that stimulate the adrenal medulla as well as cortex resulting in further release of adrenaline and cortisol and decreasing innate immunity. This neuroimmune dysfunction might have influenced the quality of the intestinal-immune barrier and generating inflammation (**Quinteiro-Filho et al., 2010**).

The exposure to stress has an important role in the pathogenesis of irritable bowel syndrome as risk, trigger and perpetuating factor. Also, it aggravated colitis with enhanced expression of pro-inflammatory cytokines, induced shortening of colonic length and colonic inflammation (**Matsunaga et al., 2011; Rho et al., 2014**). Previous study revealed that wrap-restraint stress induced histopathological alterations and activation of mast cells in colonic mucosa (**El-Drieny & Mousa, 2006**). Additionally, it resulted in severe vascular congestion with degeneration of ileal

and colonic epithelium of albino rats (**Zeybek et al., 2006 & 2007**). Also, **Rober et al. (2007)** documented the exposure to stress led to macroscopic damage of the mucosal layers of colon and increased secretion of pro and anti-inflammatory cytokines by mesenteric lymph node cells in male mice. Noise stress induced changes in gastric residual rate, small intestine propulsion rate, Guth injury score, cortisol, gastrointestinal hormones (calcitonin-gene-related peptide and motilin) and oxidative stress markers (superoxide dismutase and malondialdehyde in blood plasma of rats (**Zhang et al., 2014**).

The immobilization stress caused marked increase of biochemical parameters such as glucose, cholesterol and blood urea nitrogen (**Debnath et al., 2011**), ultrastructural alterations in the adrenal cortical zones (**El-Desouki et al., 2011**), marked increment of the weights of adrenal glands (**Littiyavirah & sajid, 2014**) and ultrastructural changeable of skeletal muscles of albino rats (**El-Desouki et al., 2014**) and alterations of the colonic mucosa (**El-Desouki et al., 2015**).

The cytoskeleton is composed of microtubules (tubulin), intermediate filaments "IFs" (cytokeratin, vimentin, desmin, glial fibrillary acidic proteins, neurofilament proteins, nuclear lamins and nestin) and microfilaments (actin). Cytoskeletal filaments play a major role in maintenance of cell shape, cell motility, cell division, organelles transport and participate in cell-cell & cell-matrix junctions, in addition to muscle contraction (**Hassan et al., 2014**).

IFs are important in allowing individual cells, tissues and whole organs to cope with various types of stress (**Pekny and lane, 2007**). IF overexpression in the response to stress leads to new filament formation and generation of additional soluble subunits pools available to buttress existing filaments and other IF subcellular compartments and protect from stress, e.g. when moderate shear stress was applied to cells for a short period of time, phosphorylation was noticed to be associated with building of keratins into thick tonofibrils to enhance the ability of cells to resist mechanical stress (**Flitney et al., 2009**). IFs have been shown to interact with receptors, kinases, and other key determinants of signal transduction machinery influencing the operation of signal determinants in various processes including stress response and tissue growth (**Pallari, 2010**).

Keratins are found in the epithelial cells and participate in epithelial cell protection from mechanical and non mechanical stressors. Keratins are used as diagnostic tumor markers, as in epithelial malignancies (**Karantza et al., 2011**). Among the most studied keratins are K8 and K18 which found in a variety of organs including gastrointestinal tract, liver, pancreas and lung. The expression of K 6/16/17 is triggered in epithelial injuries (**Moll et al., 2008**). Cytokeratin 19 is most abundant at the apical end below microvilli. Defects in Ck19 expression affect the polarity of the cells. In rat intestine staining of CK8/21 is observed at the cell periphery of absorptive cells while Ck19 is observed at the central region (**Habtezion et al., 2011**).

Vimentin is present in mesenchymal cells. It is found in almost sarcomas and melanomas but is variable in lymphomas and even some carcinomas (**Baharami et al., 2008**). It may be coexpressed with cytokeratins in a wide range of carcinomas and other tumors. Vimentin is proposed to constitute a regulatory structure at the receptor enabling efficient signal transmission (**Kumar et al., 2007**). Increased levels of methylated vimentin have been observed in colon and upper gastrointestinal tract cancer and highly expressed in the cytoplasm of fibroblasts, T&B lymphocytes and hormone independent mammary carcinoma cell lines (**Hassan et al., 2014**).

Benzodiazepines (BDZ) such as diazepam (Dz) are used as anxiolytic, sedative, hypnotic, muscle relaxant and anticonvulsant properties in the treatment of a variety of neuropsychiatric disorders including anxiety and depression which are often related to disturbances in the activity of the HPA-axis (**Strac et al., 2012**). Dz affects the central nervous system through specific binding sites on γ -aminobutyric acid (GABA)-gated chloride channels called GABA-receptor-Chloride-complex (**Engel et al., 2007**). Peripheral-type binding sites for BDZ have also been identified for them in human stomach, small intestine, colon, liver, pancreas, lung, testis, breast, ovary and on the inner and outer mitochondrial membranes (**Bribes et al., 2004**).

Dz decreased anxiety-like reactivity and reduced intra-hippocampus corticosterone concentrations in stressed mice (**Béracochéa et al., 2011**). Dz slowed the progress of chronic stress induced-impairment of hippocampal structural plasticity and depression like behavior in mice by normalizing glucocorticoids (**Zhao et al., 2012**). Moreover, **El-Desouki et al. (2015)** demonstrated that the Dz improved the histopathological alterations of the colonic mucosa of the immobilized-stressed albino rats.

As stress is increasing in our life day by day, the present study was planned to investigate the effects of immobilization stress on the cytoskeletal intermediate filaments of the colon of albino rats and the possible ameliorative role of diazepam.

MATERIALS AND METHODS

Animals:- Sixty adult male albino rats weighing 110 ± 5 g were used in the present experiment. The animals were housed in environmentally controlled optimal conditions for one week in accordance with the Ethics Committee of Accommodation and Care for Animals. Diet and water were allowed *ad-libitum*. Rats were exposed to stress for 2 hrs daily between 9:00 and 11:00 a.m. The animals were placed individually in wire mesh restrainers ($5 \times 7 \times 12$ cm in dimension) as described by **Soliman (2006)**. This procedure effectively restricted movement of the animal.

Treatment:- Stressed-rats were injected intraperitoneally (i.p.) with the therapeutic dose of diazepam (0.1 mg/kg b.w. according to **Paget & Barens (1964)**), diluted in distilled water, daily for 30 days. Diazepam was received from Amoun Pharmaceutical Industries Co. Cairo, Egypt.

Experimental design:- The rats were divided into 6 equal groups, 10 animals/each. Group I: served as control; Group II: rats injected daily with diazepam only for 30 days; Group III: stressed- rats for 5 days; Group IV: stressed -rats for 30 days; Group V: stressed-rats for 5 days and treated with diazepam for 30 days; Group VI: stressed-rats for 30 days and treated with diazepam for 30 days. At the end of each experimental period, the blood sera were collected to measure the level of cortisol and rats were sacrificed by decapitation. Serum cortisol was determined by using a radio-immunoassay kit (RIA) (biochemical, Costa Mesa, CA, USA) and the values were expressed as Ug cortisol/dl serum (**Koko et al., 2004; Ulrich-Lai et al., 2006**). The colon specimens were carefully removed, cut into small pieces then fixed in 10 % neutral formalin for 24 hrs and processed to get sections of 5µ thickness. Paraffin sections of the colon and monoclonal antibodies against either cytokeratin (**anti-CK AE1/AE3**) or vimentin (**V9**) were used (received from Dako Carpinteria, CA 93013 USA.). Avidin-biotin immunoperoxidase technique is applied in which a biotinylated secondary antibody reacts with peroxidase conjugated streptavidin molecules. Colour reaction was developed by using diaminobenzidine (DAB) that gave a brown colour. Haematoxylin was used for counterstaining (**Hsu et al., 1981 & Toti et al., 2005**).

Statistical analysis:- All values were expressed as Mean ± SD. Statistical significance was determined using one way ANOVA followed by Dunnett's comparison test.

RESULTS

I- Effect of Immobilization-stress and diazepam on cortisol levels:

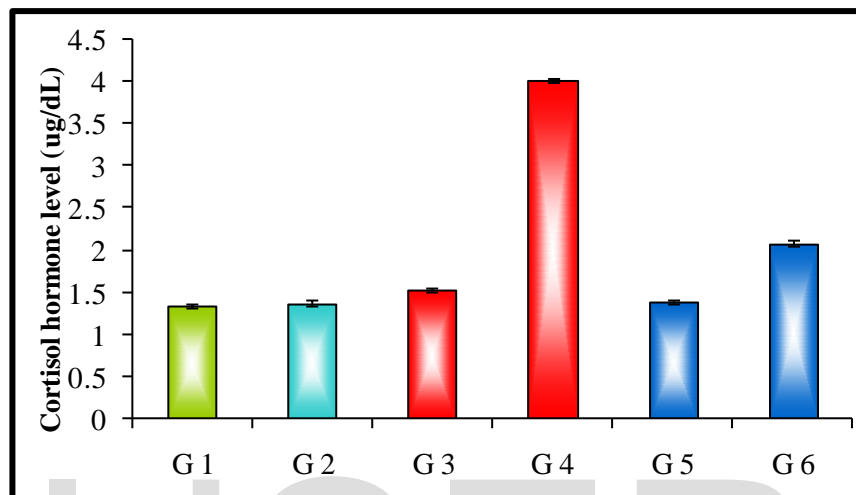
The cortisol hormone values were measured in the blood sera of rats. The value was 1.35Ug/dl in a control rat and cortisol hormone of diazepam treated rats was 1.38 Ug/dl. After 5 days of stress, the hormone levels in the blood sera were increased to 1.53Ug/dl. The increment of the hormone levels continued after 30 days of stress where it reached 4.03Ug/dl. Then, the cortisol levels in stressed rats for 5 days and treated with diazepam for 30 days decreased to reach 1.4Ug/dl, while those stressed for 30 days and treated with diazepam for 30 days decreased to 2.09Ug/dl (Table 1 and Histogram 1).

Table 1: Effect of stress and diazepam treatment on the levels of cortisol hormone

Groups	Cortisol hormone level (ug/dL)	
	Mean	SD
G1 control gp	1.35	0.03
G2 control+Dz	1.38	0.04
G3 Stressed-rats for 5 days	1.53	0.03
G5 Stressed-rats for 30 days	4.03	0.02
G5 Stressed-rats for 5 days +Dz	1.40	0.02
G6 Stressed-rats for 30 days +Dz	2.09	0.03

P-value	G1&G2	0.796
	G1&G3	0.005*
	G1&G4	<0.001*
	G3&G5	<0.001**
	G4&G6	<0.001**

All values are mean \pm SD, n-10 animals in each group; P* < 0.001 significant increase as compared to control; P** < 0.001 significant decrease as compared to stress.



Histogram 1: The correlation between stresses-rats gps, diazepam treatment gps and the levels of cortisol hormone.

II- Immunohistochemical observations:-

A. Cytokeratin:-

A1. Control group:

The cells of the colonic mucosa of control rats expressed normal cytokeratin immunoreactivity at the apical part and the lateral borders of epithelia and goblet cells (Fig.1). The treatment of normal rats with diazepam only for 30 days revealed no changes in cytokeratin immunoreaction pattern (Fig. 2).

A2. Stressed rats groups:

The immobilized-stressed rats for 5 and 30 days revealed marked intense cytokeratin immunoreactivity at the apical part and the lateral borders of epithelial and goblet cells (Figs.3&4).

A3. Treated-rats groups:

After treatment of the stressed-rats for 5 and 30 days with diazepam daily at a dose 0.1 mg/kg b.w. for 30 days, a marked decrease of cytokeratin immunoreactivity of the epithelia and goblet cells was demonstrated. Such reactivity was approximately similar to the control form (Figs. 5&6). The nuclei of such cells exhibited no reaction and stained with hematoxylin.

B. Vimentin:-

B1. Control group:

The colonic mucosa of the control rats showed the normal vimentin immunoreactivity in the form of brown colour filaments stained with avidin-biotin immunoperoxidase technique, vimentin expressed in the lamina propria and the blood vessel walls of the colonic mucosa. The normal unstressed-rats treated with diazepam only with a daily dose of 0.1 mg/kg b.w. for 30 days expressed vimentin approximately similar to the control ones (Figs. 7&8).

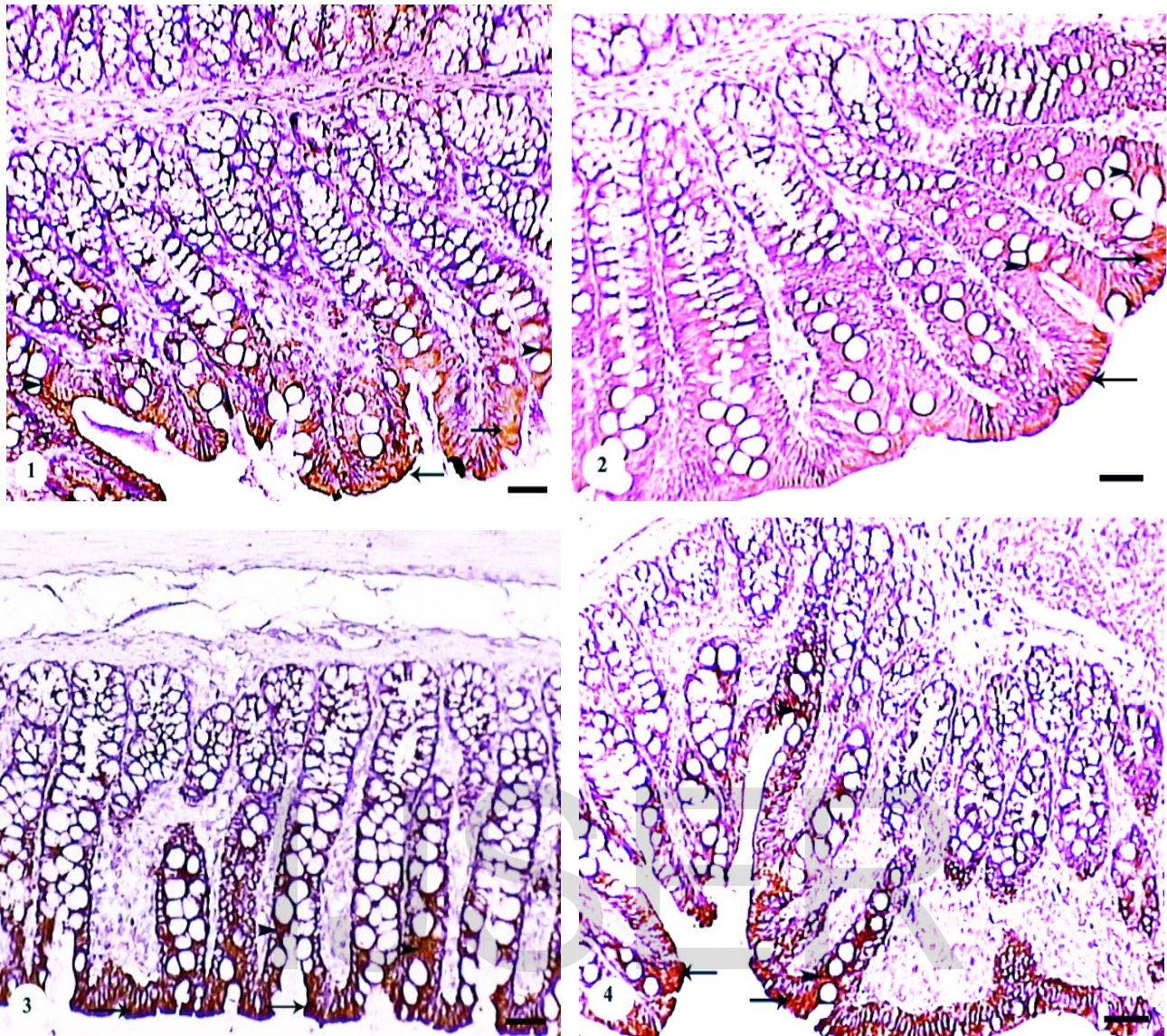
B2. Stressed rats groups:

The immobilized-stressed rats for 5 and 30 days manifested obvious intense vimentin immunoreactivity in the lamina propria and the blood vessel walls of the colonic mucosa (Figs. 9&10)

B3. Treated-rats groups:

The treatment of the stressed-rats for 5 and 30 days with diazepam at a dose 0.1 mg/kg b.w. for 30 days demonstrated a noticeable decrease of vimentin immunoreactivity in the lamina propria and the blood vessel walls of the colonic mucosa. Such reactivity was almost similar to the control ones (Figs. 11&12). The cell nuclei in all animal groups are stained blue colour with hematoxylin.

IJSER



- Fig.(1): Cross section of the colonic mucosa of a control normal rat showing the normal cytokeratin immunoreactivity at the apical part of the epithelial cells (arrows) and goblet cells (arrowheads). (Cytokeratin immunostain, Bar = 12.5 μ m).
- Fig. (2): Cross section of the colonic mucosa of a normal rat treated with diazepam for 30 days showing the normal cytokeratin immunoreactivity at the apical part of the superficial epithelial cells (arrows) and goblet cells (arrowheads). (Cytokeratin immunostain, Bar = 12.5 μ m).
- Fig. (3): Cross section of the colonic mucosa of a rat-stressed for 5 days showing intense cytokeratin immunoreactivity at the apical part of the epithelial cells (arrows) and goblet cells (arrowheads). (Cytokeratin immunostain, Bar = 12.5 μ m).
- Fig. (4): Cross section of the colonic mucosa of a rat-stressed for 30 days showing an obvious increase cytokeratin immunoreactivity at the apical part of the epithelial cells (arrows) and goblet cells (arrowheads). (Cytokeratin immunostain, Bar = 12.5 μ m).

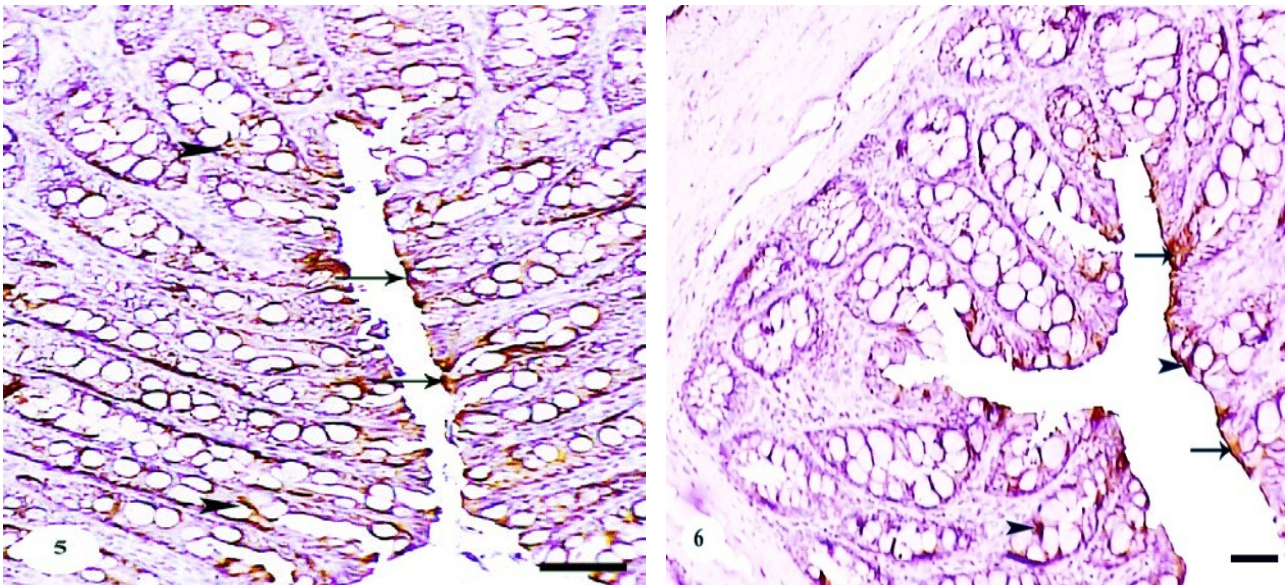


Fig. (5): Cross section of the colonic mucosa of a rat-stressed for 5 days and treated with diazepam for 30 days showing a noticeable decrease of cytokeratin immunoreactivity at the apical part of the epithelial cells (arrows) and goblet cells (arrowheads). (Cytokeratin immunostain, Bar = 12.5 μ m).

Fig. (6): Cross section of the colonic mucosa of a rat-stressed for 30 days and treated with diazepam for 30 days showing an obvious decrease of cytokeratin immunoreactivity at the apical part of the epithelial cells (arrows) and goblet cells (arrowheads). (Cytokeratin immunostain, Bar = 12.5 μ m).

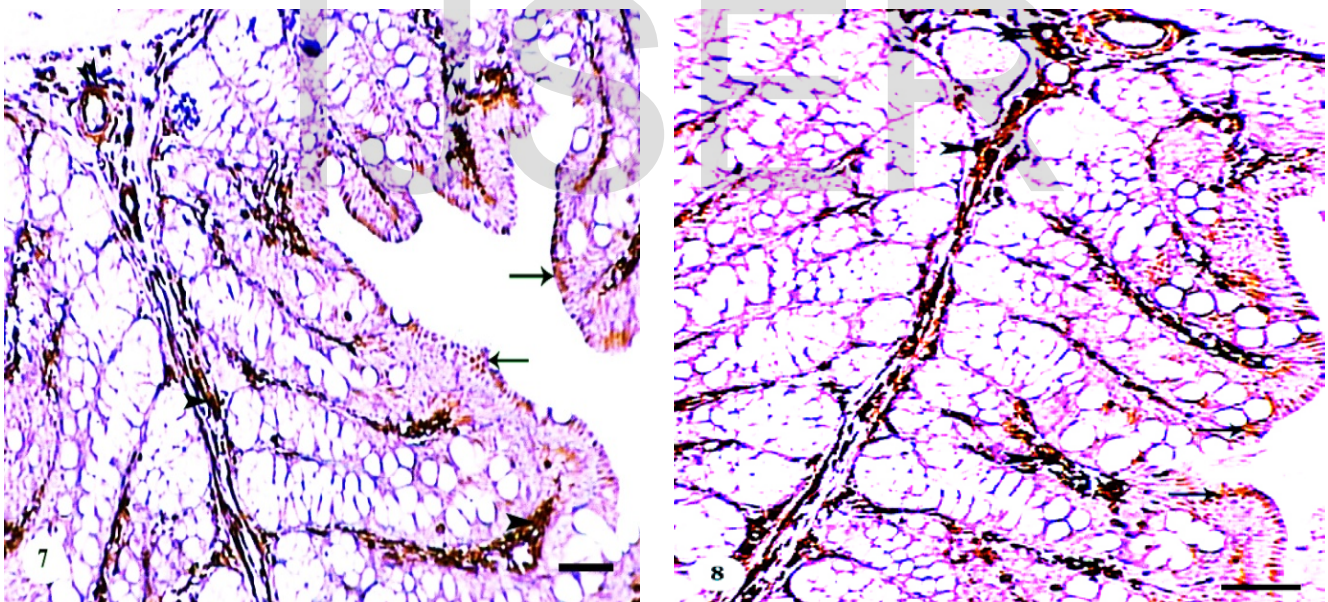


Fig. (7): Cross section of the colonic mucosa of a control rat showing the normal vimentin immunoreactivity in the lamina propria (arrow head), blood vessels (double arrowheads) and the epithelial cells (arrows). (Vimentin immunostain, Bar = 12.5 μ m.)

Fig. (8): Cross section of the colonic mucosa of a rat treated with diazepam for 30 days showing approximately the normal vimentin immunoreactivity in the lamina propria (arrow head), blood vessels (double arrowheads) and the epithelial cells (arrows). (Vimentin immunostain, Bar = 12.5 μ m.)

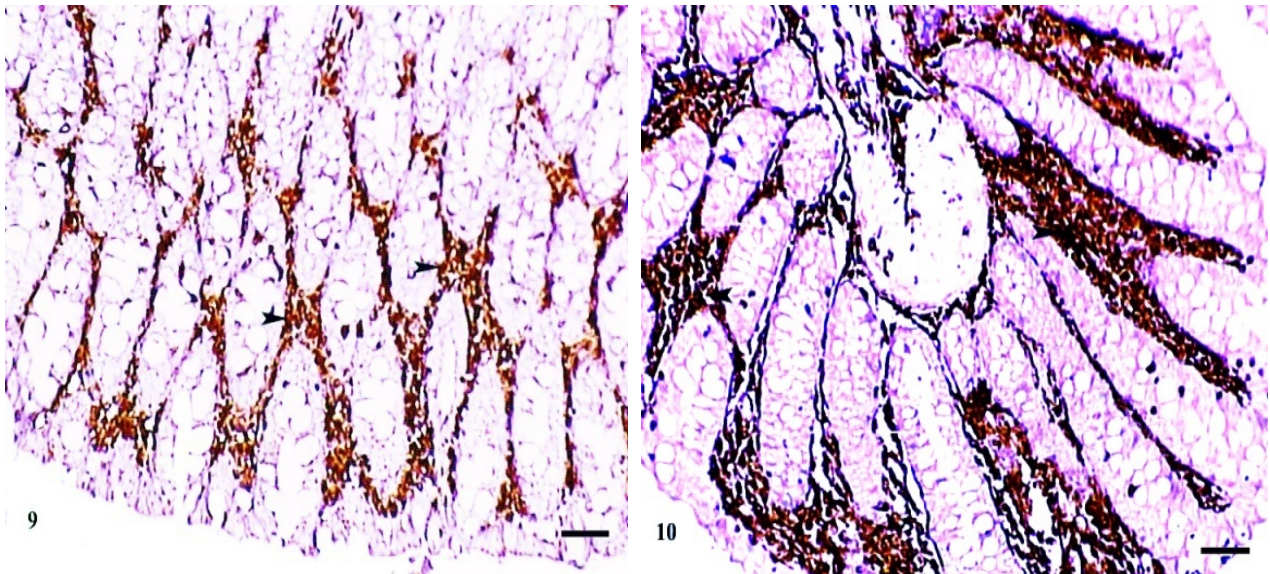


Fig . (9): Cross section of the colonic mucosa of a rat-stressed for 5 days showing an obvious intense vimentin immunoreactivity in the lamina propria (arrowhead). (Vimentin immunostain, Bar = 12.5 μ m).

Fig. (10): Cross section of the colonic mucosa of a rat-stressed for 30 days showing a marked increment of vimentin immunoreactivity in the lamina propria (arrowhead). (Vimentin immunostain, Bar = 12.5 μ m).

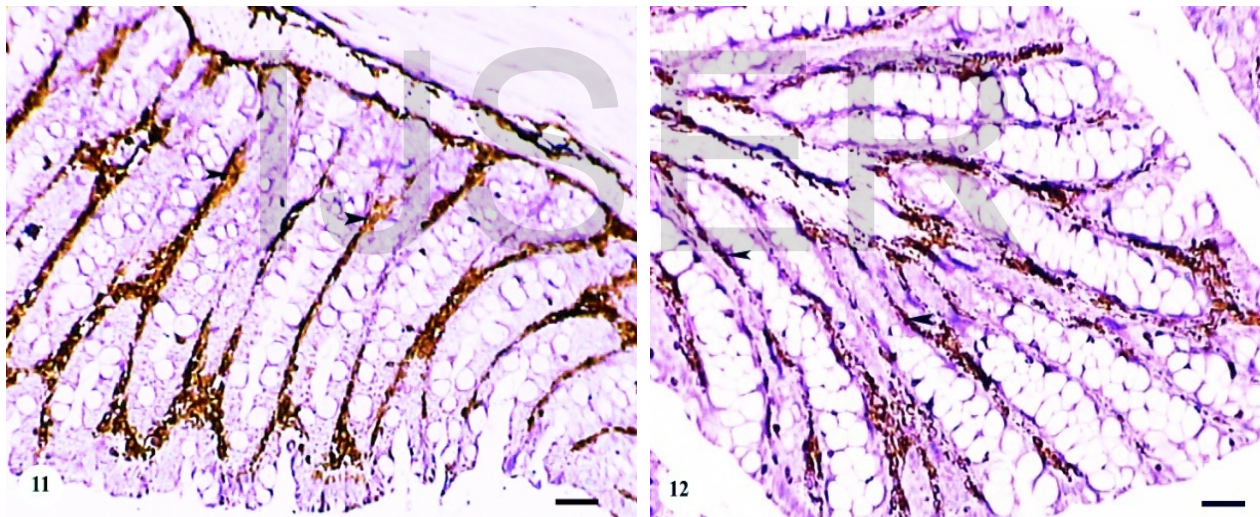


Fig. (11): Cross section of the colonic mucosa of a rat-stressed for 5 days and treated with diazepam for 30 days showing a noticeable decrease of vimentin immunoreactivity in the lamina propria (arrowheads). (Vimentin immunostain, Bar = 12.5 μ m).

Fig. (12): Cross section of the colonic mucosa of a rat-stressed for 30 days and treated with diazepam for 30 days showing a marked decrease of vimentin immunoreactivity in the lamina propria (arrowheads). (Vimentin immunostain, Bar = 12.5 μ m).

DISCUSSION

In modern society, individuals often suffer from various kinds of stress in their daily life. Stress and anxiety are believed to play a major role in developing functional gastrointestinal disorders. Psychological stress aggravated colitis with enhanced expression of pro-inflammatory cytokines. Stress also induced shortening of colonic length and colonic inflammation. Both the

epithelial cells and macrophages expressed interleukin-18 in the colonic mucosa of murine colitis (**Matsunaga et al., 2011**). Restraint stress reduced the levels of antioxidants in the normal colon and chronic stress worsened the extent of inflammation in colitis (**Israeli et al., 2008**). Also, stress has an important role in the pathogenesis of irritable bowel syndrome as risk, trigger and perpetuating factor (**Rho et al., 2014**).

The current work revealed that the immobilized-stressed rats for two durations, 5 and 30 days (acute and chronic) recorded the increment of cortisol hormone levels and obvious alterations were seen in cytokeratin and vimentin of colon, then treatment with diazepam at a dose 0.1 mg/kg b.w. for 30 days resulted in the decreased cortisol levels, marked improvement and restoration of the cytoskeletal cytokeratin and vimentin proteins to approximately normal form.

In accordance, acute and chronic stress increased the levels of cortisol in rats (**Çakir et al., 2010**). **Gabry et al. (2011)** declared that immobilization stress resulted in increment of cortisol level in male albino rats. Chronic immobilization stress increased the plasma corticosterone level and neuroinflammation in mice brain (**Perez Nievas et al., 2011**). Also, **El-Desouki et al. (2013 & 2015)** reported the increment of cortisol hormone in immobilized-stressed rats during acute and chronic stress. The stress induced-activation of HPA axis leads to the excessive production of free radicals which result in destructive and irreversible damage to cells. This activation disorganizes gastrointestinal hormones and up regulates oxidative stress that plays a critical role in the process of gastrointestinal motility disorders and gastric stress ulcer. These mechanisms associated with abnormal excrete of gut hormones as a result of HPA axis activation (**Zhang et al., 2013 & 2014**). Immobilization stress reduces GABA contents in mouse brains (**Gilhotra & Dhingra, 2010**). **Yang et al. (2014)** proposed that cold water intake affected the colonic motility through the involvement of oxytocin and its receptors in the colon of stressed rats.

The forced stress movement changed the keratin, desmin and neurofilaments and showed morphological alterations, these changes revealed that these filaments are highly elastic and can be stretched at the expense of reduction in filaments diameter (**Kreplak et al., 2005**). IFs, vimentin, keratin 6/16, have been demonstrated to comprise the response to stress and injury (**Wilhelmsson et al., 2004**). Severe problems in electrolyte transport have been detected in the distal colon of K8/Ko mice suffering colitis and chronic diarrhea (**Toivola et al., 2004**). Furthermore, the expression of K17 is rapidly increase in epithelial cells of the skin after injury (**Kim et al., 2006**). The dynamic changes of vimentin networks in response to hormonal stimulation have been associated with the distribution of melanosomes to the cell periphery (**Chang et al., 2009**). Vimentin mutation lead to cataract formation in animal models and humans (**Songs et al., 2009**). The specific increase of vimentin in nerve injury was reported by **Russell et al. (2010)**

Shear stress applied across the cell surface causes a structural remodeling of keratin intermediate filaments and a substantial increase in the elastic molecules of the cytoskeleton network (**Sivaramakrishnan et al., 2008**). In lung epithelial cells, shear stress (parallel or tangential force) increase keratin solubility, degeneration, aggregations and K8/18 phosphorylation within the thickened keratin filaments and associated keratin particles (**Flitney et al., 2009**). Similar to keratins, shear stress deforms vimentin networks in the blood vessels. The importance of vimentin in shear stress relate to focal contacts which became smaller and less able to adhere to the substratum in vimentin-null cells (**Tsuruta & Jones, 2003; Loufrani & Henrion, 2008**). IF levels increase dramatically (3-4 fold) despite their baseline abundance in response to stress. it is unknown whether IF overexpression protects from stress and/or promotes a regenerative response (**Toivola et al., 2010**). Also, stress exposure is associated with a discrete increase of dermal peripherin (IF found in neurons) positive free nerve endings in glabrous skin of rats (**Carunta et al., 2014**).

The treatment with diazepam to immobilized- stressed rats ameliorated the histological alterations and the impairments of cytoskeletal intermediate filaments cytokeatin and vimentin of the stomach to normal distribution (**El-Desouki et al., 2013**). Similarly, diazepam improved the changeable of cytoskeletal intermediate filaments desmin in the cardiomyofibirls of the immobilized-stressed albino rats (**El-Desouki et al., 2012**). Recently, diazepam improved the histopathological alterations of the colonic mucosa of the immobilized-stressed albino rats as; epithelial cells cytoplasmic vacuolation, pyknotic and karyolytic nuclei, desquamation of absorptive cells, detachment of cells from the basement membranes, reduction in number of superficial goblet cells, distortion of crypt architecture, marked leucocytic infiltration and increment of collagen fibers in lamina properia (**El-Desouki et al., 2015**).

Use of several antistress agents such benzodiazepines (diazepam), certain central nervous system stimulants such as amphetamine and caffeine as well as some anabolic steroids, showing significant antistress activity against various models of stress (**Nagasirish & saleem, 2014**).

Diazepam-induced antioxidant effects was due to the modulation of the GABA receptors through different benzodiazepine receptor agonists can reduce the oxidative damage produced by acute immobilization and psychological stress (**Singh & Kumar, 2008; Kumar et al., 2009**). The mechanisms producing the protective effects suggested that at least 2 important mechanisms could be take place: (1) the increased GABA receptor activation through diazepam would decrease the excitatory glutamateric transmission, thereby decreasing the excitotoxicity and (2) the activation of peripheral benzodiazepine receptors or translocator protein located at the mitochondrial inner membrane, these receptors are involved in micro- and astroglial activation and in many other

mitochondrial functions like apoptotic pathways and also participates in regulating cell sensitivity to oxidative stress (Sarnowska et al., 2009).

From the present study, diazepam is recommended to be used as a curative drug to ameliorate the histopathological alterations in the colon caused under the damaging effects of acute and chronic immobilization stress.

REFERENCES

- Baharami, A.; Truong, L. D. and Roj, y. (2008):** Undifferentiated tumor: True identity by immunohistochemistry. *Arch. Pathol. Lab. Med.*, 132: 326-348.
- Béracochea, D.; Tronche, C.; Coutan M.; Dorey, R.; Chauveau, F. and Piérard, C. (2011):** Interaction between diazepam and hippocampal corticosterone after acute stress: impact on memory in middle-aged mice. *Front. Behav. Neurosci.*, 5(14):1-9.
- Bribes, E.; Carriere, D.; Goubet, C.; Galiegue, S.; Casellas, P. and Simony-Lafontaine, J. (2004):** Immunohistochemical assessment of the peripheral benzodiazepine receptor in human tissues. *J. Histochem. Cytochem.*,52(1): 19 – 28.
- Çakir, B.; Kasımay, Ö.; Kolgazi, M.; Ersoy, Y.; Ercan, F. and Yeğen, B.C. (2010):** Stress-induced multiple organ damage in rats is ameliorated by the antioxidant and anxiolytic effects of regular exercise. *Cell Biochem. Function*, 28(6): 469-479.
- Caruntua, C.; Boda, D.; Musat, S.; Carunta, A.; Poenaru, E.; Calenic, B.; Fiedler, I. S.; Draghla, A.; Rotaru, M. and Badaru, A. I. (2014):** Stress effects on cutaneous nociceptive nerve fibers and their neurons of origin in rats. *J. Rom. Biotechnol. Lett.* Vol., 9(4): 9517-9530.
- Chang, L.; Barlan, K.; Chou, Y. H.; Grin, B.; Lakonishok, M.; Serpinskaya, A. S.; Shumaker, D. K.; Herrmann, H.; Gelfand, V. I. and Goldman, R. D. (2009):** The dynamic properties of intermediate filaments during organelle transport. *J Cell Sci* 122:2914-2923.
- Debnath, J.; Prakash, T.; Karaki, R.; Kotresha, D. and Sharma, P. (2011):** An experimental evaluation of anti-stress effects of Terminaliachebula. *J. Physiol. Biomed. Sci.*, 24: 13-19.
- El-Desouki, N. I.; Afifi, D.F; El-Refaiy, A.I. and Abdel – Kader, A.A. (2014):** Immobilization Stress- Related alterations in Ultrastructure of Skeletal Muscle of Albino Rat and the Role of Diazepam. *Res. J. Pharm. Biol. Chem. Sci.* 5(4): 574- 587.
- El-Desouki, N. I.; El-Refaiy, A. I.; Abdel-Azeem, H. and Elbaely, M.M. (2011):** Ultrastructural Study of the effect of immobilization stress on the adrenal cortex of albino rat and the curative role of diazepam. *J. Egypt. Ger. Soc. Zool.* Vol. (62C): 25 – 45
- El-Desouki, N. I.; El-Refaiy, A. I.; Afifi, D. F. and Abdel-Kader, A. A. (2012):** Histological, histochemical and immunohistochemical studies on the cardiac muscle of albino rat under immobilization stress and the possible curative role of diazepam. *Egypt. J. Exp. Biol. (Zool.)*, 8(2): 273 - 285.
- El-Desouki, N. I.; El-Refaiy, A. I.; Gabry, M. S., Ibrahim, M. A. and Mohamed, H. N. (2013):** Effect of immobilization stress on the cytoskeletal intermediate filaments of rat stomach and the possible curative role of diazepam. *J. Life Sci.*, 10 (2): 2211 – 2219.
- El-Desouki, N. I.; Gabry, M. S. and Nagi, H. M. (2015):** Beneficial role of diazepam in the histological alterations of colon post immobilization stress-induced in adult albino rats. *IJSER*, 6 (5): 432-440.

- EL-Drieny, E. and Mousa, A. M. (2006):** Histological study on the effect of stress on the colonic mucosa of adult male albino rat and the possible role of mast cells. *Egypt. J. Histol.*, 29(2): 315-326.
- Engel, J.; Solomon, M. and Jean, A. (2007):** Epilepsy A comprehensive Textbook. 2nd edn. Vol. 2. Philadelphia, P A: Lippincott Williams and Wilkins, 1433-1466.
- Flitney, E. W.; Kuczarski, E. R.; Adam, S. A. and Goldman, R. D. (2009):** Insights into the mechanical properties of epithelial cells: the effects of shear stress on the assembly and remodeling of keratin intermediate filaments. *FASEB J.*, 23(7):2110-2119.
- Gabry, M. S., El-Desouki, N. I.; El-Refaiy, A. I.; Ibrahim, M. A. and Mohamed, H. N. (2011):** Histological study on the stomach of immobilized- stressed albino rat and curative role of diazepam. *J. Egypt. Exp. Biol. (Zool)*, 7 (2): 153 – 161.
- Gilhotra, N. and Dhingra, D. (2010):** GABAergic and nitriergic modulation by curcumin for its antianxiety-like activity in mice. *Brain Res.*,1352:167–175
- Habtezion, A.; Toivola, D. M.; Strnad, P. and Omary, M. B. (2011):** Absence of keratin 8 confers a paradoxical microflora-dependent resistance to apoptosis in the colon. *Am. Nat. Acad. Sci.*, 108(4): 1445-1450.
- Hassan, N. M., Harbi, S. O., Shomo, A. I., El-Tahir , Y. I. and Ahmed, M. E. (2014):** Cytokeratin 18 and vimentin expression in breast cancer tissue from Sudanese patients. *Ann. Biol. Res.*, 5(1): 9 – 16.
- Hsu, S. M.; Raine, L., and Fanger, H. (1981):** Use of Avidin-biotin peroxidase complex (ABC) in immunoperoxidase techniques. A comparison between ABC and unlabeled antibody (PAP) procedures. *J. Histochem. Cytochem.*, 29: 557-580.
- Israeli, E.; Hershcovici, T.; Berenshtein, E.; Zannineli, G.; Wengrower, D.; Weiss, O; Chevion, M. and Goldin, E. (2008):** The effect of restraint stress on the normal colon and on intestinal inflammation in a model of experimental colitis. *J. Dig. Dis. Sci.*, 53(1): 88-94
- Karantza, V. (2011):** Keratins in health and cancer: more than epithelial cell markers. *Oncogene*, 30: 127-138.
- Kim, S.; Wong, P. and Coulombe, P. A. (2006):** A keratin cytoskeletal protein regulates protein synthesis and epithelial cell growth. *Nature* 441:362-5.
- Koko, V.; Djordjeviæ, J.; Cvijiaæ, G. and Davidoviæ, V. (2004):** Effect of acute heat stress on rat adrenal glands: a morphological and stereological study. *J. Exp. Biol.*, 207: 4225-4230.
- Kreplak, L.; Bar, H.; Letierrier, J. F.; Herrmann, H. and Aebi, U. (2005):** Exploring the mechanical behavior of single intermediate filaments. *J. Mol. Biol.*, 354: 569-577.
- Kumar, A.; Goyal, R. and Prakash, A. (2009):** Possible GABAergic mechanisms in the protective effect of allopregneonolone against immobilization stress. *Eur. J. Pharmacol.*, 602: 343-347.
- Kumar, N.; Robidoux, J.; Daniel, K. W.; Guzman, G.; Floering, L. M. and Collins, S. (2007):** Requirement of vimentin filament assembly for beta3-adrenergic receptor activation of ERK MAP kinase and lipolysis. *J. Biol. Chem.*, 282:9244-9250.
- Loufrani, L. and Henrion, D. (2008):** Role of the cytoskeleton in flow (shear stress)-induced dilation and remodeling in resistance arteries. *Med. Biol. Eng. Comput.*, 46(5): 451-460.
- Lttiyavirah, S. P. And Sajid, K. P. (2014):** Behavioral assesement of Mikania micrantha Kunth roots in Wistar albino rats. *J. Med. Plants Res.*, 8 (11): 448 – 453.

- Matsunaga, H.; Hokari, R.; Ueda, T.; Kurihara, C.; Hozumi, H.; Higashiyama, M.; Okada, Y.; Watanabe, C.; Komoto, S.; Nakamura, M.; Kawagushi, A.; Nagao, S.; Sekiyama, A. and Miura, S. (2011):** Physiological stress exacerbates murine colitis by enhancing proinflammatory cytokines expression that is dependent on IL-18. *Am. J. Physiol. Gastrointest. Liver Physiol.*, 301: G555– G564.
- Moll, R.; Divo, M. and Langbein, L. (2008):** The human keratins: biology and pathology. *J. Histochem. Cell Biol.*, 129: 705-733.
- Nagasirish, M. and Saleem, M. (2014):** Effect of whole plant of *Rostellularia diffusa* wild. On experimental stress in mice. *Pharmacogen. Mag.*, 10(3): 5614-5621.
- Paget, G. E. and Barends, J. M. (1964):** Evaluation of drug activities, 2nd ed. Laurence and Bacharach, Academic press, New York.
- Pallari, H. M. (2010):** Dynamic interplay between the intermediate filament protein nestin and cyclin-dependent kinase 5. PHD. Thesis, University of Turku, Finland.
- Pekney, M. and Lane, E. B. (2007):** Intermediate filaments and stress. *Exp. Cell Res.*, 313(10): 2244-2254.
- Perez Nievas, B. G.; Hummer Schmidt, T.; Kummer, M. P.; Terwel, D.; Leza, J.C. and Henka, M. T. (2011):** Restraint stress increases neuroinflammation independently of amyloid β Levels in amyloid precursor protein/PS1 transgenic mice. *J. Neurochem.*, 116: 43-52.
- Quinteiro-Filho, W. M.; Ribeiro, A.; De-Paula, V. F.; Pinheiro, M. L.; Sakai, M.; Sa, L. R. M.; Ferreira, A. J. P. and Palermo-Neto, J. (2010):** Heat stress impairs performance parameters, induces intestinal injury, and decreases macrophage activity in broiler chickens. *Poultry Sci.*, 89:1905–1914
- Rho, S.G.; Kim, Y.S.; Cho, S.C. and Lee, M. Y. (2014):** Sweet food improves chronic stress induced irritable bowel syndrome-like symptoms in rats. *World J. Gastroenterol.*, 20(7): 2365-2373.
- Rober, S. O., Birkender, L., Veenema, A. H., Obermiene, F., Falk, W., Stranb, R. H. and Neumann, I. D. (2007):** Adrenal insufficiency and colonic inflammation after a novel chronic psycho-social stress paradigm in mice: Implications and mechanisms. *J. Endocrinol.*, 148(2): 670 – 680.
- Russell, D.; Ross, H. and Lane, E. B. (2010):** ERK Involvement in Resistance to Apoptosis in Keratinocytes with Mutant Keratin. *J. Invest. Dermatol.*, 130:671-681.
- Sarnowska, A.; Bereswicz, M.; Zablocka, B. and Domanska-Janik, K. (2009):** Diazepam neuroprotection in excitotoxic and oxidative stress involves a mitochondrial mechanism additional to the GABA_AR and hypothermic effects. *J. Neurochem. Int.*, 55: 164-173.
- Singh, A. and Kumar, A. (2008):** Protective effect of alprazolam against sleep deprivation-induced behavior alterations and oxidative damage in mice. *Neurosci. Res.*, 60: 372-379.
- Sivaramakrishnan, S.; Degiulio, J. V.; Lorand, L.; Goldman, R. D. and Ridge, M. K. (2008):** Micromechanical properties of keratin intermediate filament networks. *PNAS*, Vol., 105(3): 889 -894
- Soliman, A. A. (2006):** Effect of stress on the mammary gland of lactating albino rat: A light and electronic microscopic study. *Egypt. J. Hisotol.*, 29(2): 259-268.
- Song, S.; Landsbury, A.; Dahm, R.; Liu, Y.; Zhang, Q. and Quinlan, R. A. (2009):** Functions of the intermediate filament cytoskeleton in the eye lens. *J. Clin. Invest.*, 119:1837-1848.
- Strac, D.S.; Muck-Seler, D. and Pivac, N. (2012):** The involvement of noradrenergic mechanisms in the suppressive effects of diazepam on the hypothalamic-pituitary-adrenal axis

activity female rats. *J. Croat. Med.*, 53(3): 214 - 223.

- Toivola, D. M.; Krishnan, S.; Binder, H. J.; Singh, S. K. and Omary, M. B. (2004):** Keratins modulate colonocyte electrolyte transport via protein mistargeting. *J. Cell Biol.*, 164:911-921.
- Toivola, D. M.; Strnad, P.; Habtezion, A. and Omary, M. B. (2010):** Intermediate filaments take the heat as stress proteins. *Trends Cell Biol.*, 20:79-91.
- Toti, P.; Regoli, M.; Nesi, G.; Occhini, R.; Bartolommei, S.; Fonzi, L. and Bertelli, E. (2005):** Nestin expression in normal adrenal gland and adrenocortical tumors. *Histol. Histopathol.*, 20: 115-120.
- Tsuruta, D. and Jones, J. C. (2003):** The vimentin cytoskeleton regulates focal contact size and adhesion of endothelial cells subjected to shear stress. *J. Cell Sci.*, 116(24):4977-4984
- Ulrich-Lai, Y. M.; Figueiredo, H. F.; Ostrander, M. M.; Choi, D. C.; Engeland, W. C. and Herman, J. P. (2006):** Chronic stress induces adrenal hyperplasia and hypertrophy in a subregion-specific manner. *Am. J. Physiol. Endocrinol. Metab.*, 291(5): 965-973.
- Wilhelmsson, U.; Li, L.; Pekna, M.; Berthold, C. H.; Blom, S.; Eliasson, C.; Renner, O.; Bushong, E.; Ellisman, M.; Morgan, T. E. and Pekny, M. (2004):** Absence of glial fibrillary acidic protein and vimentin prevents hypertrophy of astrocytic processes and improves post-traumatic regeneration. *J. Neurosci.*, 24:5016-5021.
- Yang, X.; Xi, T. F.; Li, Y. X.; Wang, H. H.; Qin, Y.; Zhang, J. P.; Cai, W. T.; Huang, M. T.; Shen, J. Q.; Fan, X. M.; Shi, X. Z. and Xie, D. P. (2014):** Oxytocin decreases colonic motility of cold water stressed rats *via* oxytocin receptors. *World J. Gastroenterol.*, 20(31): 10886-10894
- Zeybek, A.; Ercan, F.; Çetinel, S.; Cikler, E.; Saglam, B. and Sener, G. (2006):** Taurine ameliorates water avoidance stress-induced degeneration of gastrointestinal tract and liver. *J. Dig. Dis. Sci.*, 51: 1853-1861.
- Zeybek, A.; Ercan, F.; Çetinel, S.; Cikler, E.; Saglam, B. and Sener, G. (2007):** Protective effects of aqueous garlic extract in reducing water avoiding stress-induced degeneration of the stomach, ileum and liver: morphological and biochemical study. *J. Dig. Dis. Sci.*, 52: 2984-2992.
- Zhang, L.; Gong, J. T.; Zhang, H. Q.; Song, Q. H.; Xu, G. H.; Cai, L.; Tang, X. D.; Zhang, H. F.; Liu, F. E.; Jia Z. S. and Zhang, H. W. (2014):** Melatonin Attenuates Noise Stress-induced Gastrointestinal Motility Disorder and Gastric Stress Ulcer: Role of Gastrointestinal Hormones and Oxidative Stress. *J. Neurogastroenterol. Motil.*, 26:1-11.
- Zhang, L.; Zhang, H. Q.; Liang, X. Y.; Zhang, H. F.; Zhang, T. and Liu, F. E. (2013):** Melatonin ameliorates cognitive impairment induced by sleep deprivation in rats: role of oxidative stress, BDNF and CaMKII. *Behav. Brain Res.*, 256: 72-81.
- Zhao, Y.; Wang, Z.; Dai, J.; Chen, L.; Huang, Y. and Zhan, Z. (2012):** Beneficial effects of benzodiazepine diazepam on chronic stress-induced impairment of hippocampal structural plasticity and depression-like behavior in mice. *Behav. Brain Res.*, 228: 339-350.